

Peyronie's disease—the Plymouth experience of extracorporeal shockwave treatment

R. HAMM, E. MCLARTY,* J. ASHDOWN,† S. NATALE and A. DICKINSON

Torbay Hospital, Devon, *The Royal Sussex County Hospital, Brighton, and †Derriford Hospital, Plymouth, Devon, UK

Objective To describe our experience of the use of extracorporeal shockwave treatment (EST) for Peyronie's disease.

Patients and methods The study included 28 patients (mean age 57 years, range 34–72) with stable Peyronie's disease who were treated with 3.9 (3–5) sessions of EST to the Peyronie's plaque. The patients' erectile function, pain and penile angle were assessed before and after treatment with EST.

Results Of the 28 patients, 20 felt that their erection improved after the procedure; 11 patients were able to recommence sexual intercourse and the index of erectile function increased in all but one patient.

Conclusion EST produces a significant improvement in pain and penile angle, with no serious complications.

Keywords Peyronie's disease, treatment, extracorporeal shockwave treatment

Introduction

Peyronie's disease, named after Francois de la Peyronie [1], was first described over 200 years ago but remains incompletely understood. The disease is more common in men aged >40 years, with an incidence of 1–4%, and seems to be more common in Caucasians. The exact cause of the disease remains unknown but several hypotheses have been proposed; first, that the lesion results from perivascular inflammation [2]; second, it arises from an association with trauma in a susceptible individual, possibly during sexual intercourse [3]; third, there are reports of a genetic predisposition to the disease, linked to HLA-DQ5 [4]. Iatrogenic plaque formation may also occur after long-term injection with intracavernosal substances used in the treatment of impotence. The course of the disease tends to run over 1–1.5 years; as the remodelling of the plaque becomes complete the pain associated with the inflammatory process tends to disappear and the effects of the lesion become static or even start to recede.

The application of extracorporeal shockwaves for treating Peyronie's disease was first described in the 1980s, using the piezoelectric shockwave generator. Since then several studies have reported the efficacy of this treatment [5–11]. In Peyronie's disease the therapeutic aim is to destroy the plaque and improve the elastic quality of the tissues, restoring erectile function and alleviating pain.

Patients and methods

Our unit has been using extracorporeal shockwave treatment (EST) to treat Peyronie's disease since 1998, using the Storz Minilith SL1 machine (Storz GmbH, Germany). This machine has an adjustable electromagnetic pressure wave source with a parabolic reflector, an adaptable focal size, and a 7.5 MHz in-line ultrasound scanner for precisely locating the target, suspended on a flexible arm. This arm allowed the accurate delivery of shocks to a patient seated in a comfortable position.

The study included 28 men (mean age 57 years, range 34–72) recruited from general urology clinics, who had had Peyronie's disease for >1 year and who were deemed to be in the stable phase of the disease. The diagnosis was made from a history and examination. All patients described a deformity of the penis and the clinician confirmed the diagnosis by palpating the thickened plaques. Further investigation of the patient was not usually required to make the diagnosis.

The initial assessment involved administering the International Index of Erectile Function (IIEF) [12], a Sexual Function questionnaire [13] and a specifically developed linear pain score questionnaire. An artificial erection was induced using an intracavernosal injection with alprostadil (Caverject, Pharmacia and Upjohn, UK). The dose was titrated for each patient, from 2.5 µg in 2.5 µg increments, until a normal erection was achieved; the penis was then photographed and the penile angle measured. The size and site of the plaques was recorded, the size of the plaque being confirmed by ultrasonography (Fig. 1).

Accepted for publication 21 February 2001

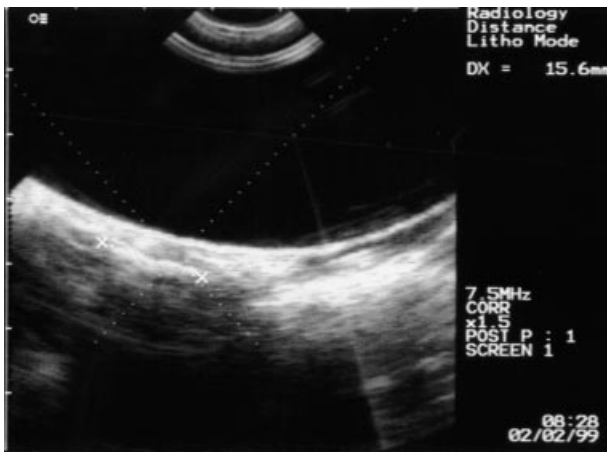


Fig. 1. Localizing a Peyronie's plaque using ultrasonography before treatment.

The patients underwent a mean (range) of 3.9 (3–5) treatments of EST with a maximum of 3000 shocks per plaque at a power level of 2–5. The plaque was located using in-line ultrasonography and palpation, and by the patients being able to feel a 'prickling' sensation in the plaque during therapy. The effect of the treatment was assessed subjectively by the patients, by objective evidence from the photographs and penile angle before treatment, and by re-administering the questionnaires.

Results

Of the 28 patients treated, 20 (71%) reported an improvement in their erection after EST. Before treatment 16 patients had been unable to have penetrative coitus but at the follow-up 11 of these patients had recommenced sexual intercourse. The IIEF score increased in all but one patient and improved overall ($P < 0.001$, Wilcoxon matched-pairs signed-rank sum test); the mean improvement was 12.5. Fifteen patients reported a decrease in the angle of the penis and three reported that their penis was now almost straight (Fig. 2). In no patient did the angle deteriorate; 10 patients also felt that the rigidity of their erection had improved. Sixteen patients reported pain during erection and intercourse before treatment, and in 13 this pain improved. The feeling of tightness experienced in the area of the plaque during erection was relieved in all patients.

Ultrasonographic measurements of the plaque were unreliable; there was no correlation between the change in plaque size and any symptomatic improvement. Ultrasonography did not detect seven plaques that remained easily palpable; 12 patients reported that subjectively the plaque had diminished.

There were no major complications and the treatment was well tolerated, with all patients complying. Half the

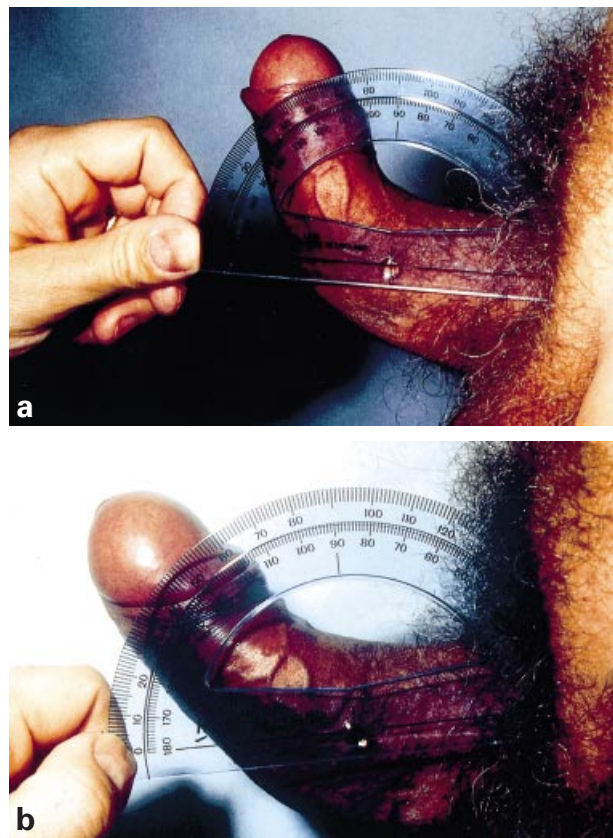


Fig. 2. The angulation of the penis before (a) and after treatment (b).

patients had minor penile bruising, one developed a minor urethral haemorrhage and one developed a penile blister, but both settled with conservative management.

Discussion

This report represents the second experience of the use of EST in the UK; seven other studies (reported as papers or abstracts) have investigated the effectiveness of EST as a treatment for Peyronie's disease [5–11]. Including the present study, 290 patients have been treated in total. All the studies except that by Abdel-Salam *et al.* [10] used the Storz Minilith SL1 (the latter used the Siemens Lithostar). The mean (range) number of sessions per patient was 3 (1–10) and the number of shocks per session was 2000–4000. In no studies was it found necessary to use analgesics.

There are various medical treatments for Peyronie's disease; Devine and Horton [14] reported that Peyronie's disease resolved, improved or became static in two-thirds of patients taking vitamin E (200 mg with each meal or 400 mg twice daily). Potassium para-aminobenzoate is commonly prescribed but the treatment requires taking 24 tablets/day and can have significant gastrointestinal side-effects [15]. Other treatments include tamoxifen

(in the early stages) [16] and more recently interferon $\alpha 2b$ [17].

More invasive treatments have included the direct injection of agents into the plaques; collagenase was proposed [18] but a double-blind evaluation showed that it was not clearly effective. Although radiation therapy may lead to tissue atrophy, low-dose radiation can help in patients with severe pain during the acute phase [19]. No noninvasive treatment has so far provided a cure for the residual penile deformity and for those patients who are unable to achieve satisfactory sexual function; surgery remains the mainstay of treatment.

Surgical procedures undertaken include either excision of the plaque, replacing the deficiency in the sheath with a dermal graft [20,21], dura [22], synthetic material (e.g. silicone, Dacron) or venous patch, or compensating for the curvature on one aspect by plicating the opposite aspect of the sheaths of the corpora cavernosa (Nesbitt's operation [23–25]).

Patient satisfaction after surgical treatment for Peyronie's disease is variable. Nesbit-type procedures that involve plication opposite the plaque lead to shortening of the penis and this can cause considerable patient anxiety. Frank *et al.* [26] found that 44% of men undergoing Nesbit's procedure felt the result was excellent, but 37% were only moderately satisfied and 19% dissatisfied. Wild *et al.* [21] reported that after plaque excision and grafting, 75% of patients were happy with the results. Kaufman *et al.* [26] assessed the satisfaction of men who had a penile prosthesis inserted, finding that only half were satisfied with the results, with 30% being 'somewhat satisfied'. From these results, surgery is apparently not the ideal solution for treating Peyronie's disease and there is room for the development of other treatment methods.

Combining the present results with those from other series, the proportion of patients showing an improvement in angulation was 33–64%. Mirone [5] made no comment on the percentage of patients reporting an improvement, but stated that patients were 'improved'; Nespoli *et al.* [8] stated that their patients had a 10–50% reduction in the angulation present before treatment, and in some patients the curvature was completely resolved (6–17%). Sexual intercourse was resumed after being absent before treatment by 47% (10/23) patients in the study by Butz and Teichart [9] and by 69% (13 of 18) in the present study. All studies showed an improvement in pain after treatment, of 40–100%. Complete failure of the treatment was reported in only three studies, with an incidence of 17–41%. Overall, 54–76% of patients were satisfied; this compares favourably with the satisfaction after surgical procedures noted earlier. The cost of treatment for the present patients was about £120 per patient and considerably less than the cost of surgery.

There were no serious complications in any of the studies, with petechiae, skin haematoma and urethral bleeding being the most common; blistering was only reported as a complication in the present study. In the reported studies, all patients with complications were managed conservatively.

The results of the present and previous studies clearly show that EST is well tolerated, with no serious complications. It has considerable benefit in reducing the pain and angulation, and increasing the ability for coitus in a significant number of patients. A multicentre randomized controlled trial should be conducted to further investigate this treatment and assess the long-term follow-up.

References

- 1 de la Peyronie F. Sur quelques obstacles qui s'opposent a l'ejaculation naturelle de la semence. *Memoires de l'Academie de Chirurgie* 1743; **1**: 318
- 2 Smith BH. Peyronie's disease. *Am J Clin Pathol* 1966; **45**: 670
- 3 Devine CJ Jr, Somers KD, Wright GL Jr *et al.* A working model for the genesis of Peyronie's disease derived from its pathobiology. *J Urol* 1988; **139**: 286A(Abst495)
- 4 Nachtsheim DA, Rearden A. Peyronie's disease is associated with an HLA Class II antigen HLA DQ5 implying an autoimmune aetiology. *J Urol* 1996; **156**: 1330–4
- 5 Mirone V. Old and new: reality and utopia in medical treatment of IPP. *Acta Urol Ital* 1998; **12**: 183–8
- 6 Colombo F, Baroni P, Serrago M, Mantovani F, Patelli E, Pisani E. The use of shock waves in the treatment of Peyronie's disease. *Congress of the Italian Andrological Society* 1997
- 7 Colombo F, Serrago M, Esposito N, Patelli EF, Mantovani and Pisani E. Shock waves in La Peyronie's disease: the preliminary report. *Proceedings of the American Urologic Association* 1998
- 8 Nespoli R, Gianneo E, Conti G *et al.* Extracorporeal shock wave treatment (ESWT) in la Peyronie disease (PD): a new therapy? *Proceedings of the European Association of Urology*, 1998
- 9 Butz M, Teichert HM. Treatment of Peyronie's disease (PD) by extracorporeal shock waves (ESW). *Proceedings of the American Urologic Association* 1998
- 10 Abdel-Salam Y, Budair Z, Renner C *et al.* Treatment of Peyronie's disease by extracorporeal shockwave therapy: evaluation of our preliminary results. *J Endourol* 1999; **13**: 549–52
- 11 Husain J, Lynn NNK, Jones DK, Collins GN, O'Reilly PH. Extracorporeal shock wave therapy in the management of Peyronie's disease: initial experience. *BJU Int* 2000; **86**: 466–8
- 12 Rosen RC, Riley A, Wagner G, Osterloh IH, Kirkpatrick J, Mishra A. The International Index of Erectile Function (IIEF): a multidimensional scale for assessment of erectile dysfunction. *Urology* 1997; **49**: 822–30

- 13 Donovan J. Measurement of symptoms, quality of life and sexual function. *BJU Int* 2000; **85** (Suppl 1): 10–9
- 14 Devine CJ Jr, Horton CE. The surgical treatment of Peyronie's disease with a dermal graft. *J Urol* 1974; **111**: 44
- 15 Carson CC. Potassium para-aminobenzoate for the treatment of Peyronie's disease: is it effective? *Tech Urol* 1997; **3**: 135–9
- 16 Teloken C, Rhoden EL, Graziotin TM, Ros CT, Sogari PR, Souter CA. Tamoxifen versus placebo in the treatment of Peyronie's disease. *J Urol* 1999; **162**: 2003–5
- 17 Ahaja S, Bivakicquin TJ, Case J *et al.* A pilot study demonstrating clinical benefit from intralesional interferon alpha 2B in the treatment of Peyronie's disease. *J Androl* 1999; **20**: 444–8
- 18 Gelbard MK, Linder A, Kaufman JJ. The use of collagenase in the treatment of Peyronie's disease. *J Urol* 1985; **134**: 280
- 19 Carson CC, Coughlin PW. Radiation therapy for Peyronie's disease: is there a place? *J Urol* 1985; **34**: 684–6
- 20 Horton CE, Devine CJ. Peyronie's disease. *Plastic Reconstructive Surgery* 1973; **52**: 503–9
- 21 Wild RM, Devine CJ, Horton CE. Dermal graft repair of Peyronie's disease: survey of 50 patients. *J Urol* 1979; **121**: 47–50
- 22 Kelami A. Surgical treatment of Peyronie's disease using human dura. *Eur Urol* 1977; **3**: 191–2
- 23 Pryor JP, Fitzpatrick JM. A new approach to the correction of the penile deformity in Peyronie's disease. *J Urol* 1979; **122**: 622–3
- 24 Frank JD, Mors B, Pryor JP. The surgical correction of erectile deformities of the penis of 100 men. *Br J Urol* 1981; **53**: 645–7
- 25 Lemberger RJ, Bishop MC, Bates CP. Nesbit's operation for Peyronie's disease. *Br J Urol* 1984; **56**: 721–3
- 26 Kaufman JJ, Boxer B, Quin MC. Physical and psychological results of penile prostheses: a statistical survey. *J Urol* 1981; **126**: 173

Authors

- R. Hamm, FRCS, SpR Urology.
 E. Mclarty, FRCS, Urology Research Fellow.
 J. Ashdown, Urology Research Nurse.
 S. Natale, FRCS, Urology Associate Specialist.
 A. Dickinson, FRCS(Urol), Consultant Urologist.
 Correspondence: Miss R. Hamm, Department of Urology, Torbay Hospital, Lawes Bridge, Torquay, TQ2 7AA, UK.